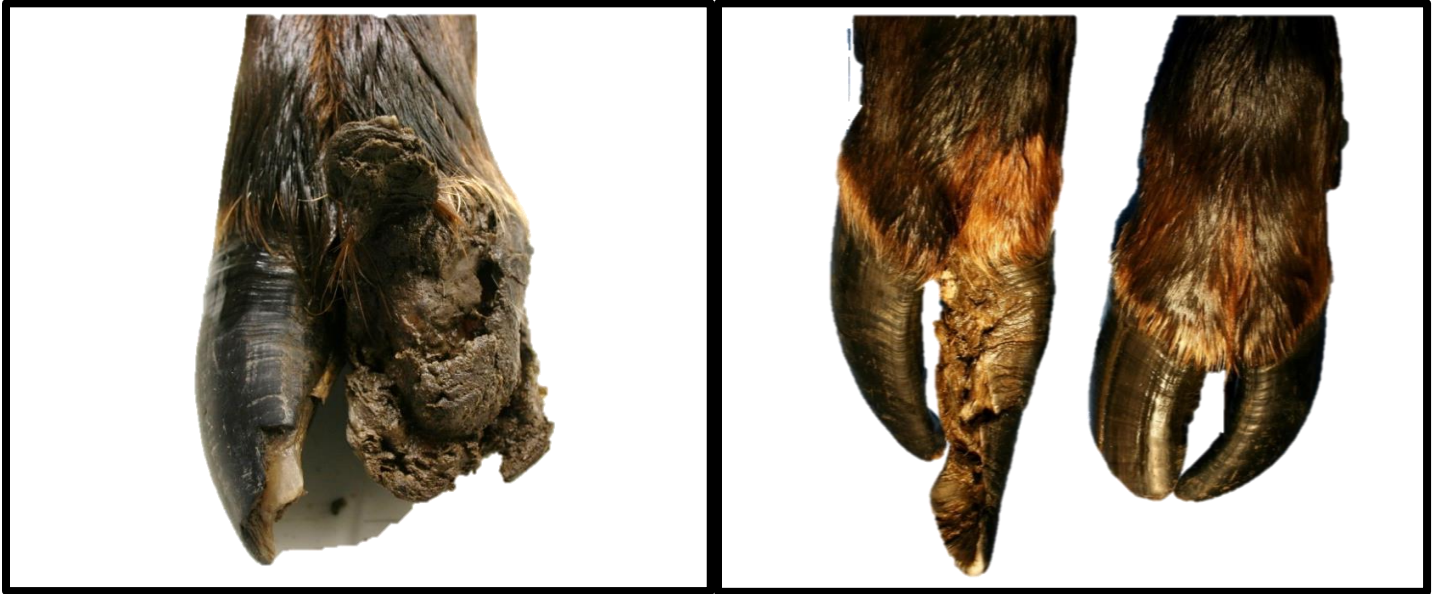

Elk Hoof Disease Fact Sheet



What is elk hoof disease?

Elk hoof disease, now referred to as Treponeme associated hoof disease (TAHD), is a bacterial-associated syndrome causing severe lameness in elk. The condition initially appeared in southwestern Washington elk herds between the late 1990's and early 2000s. A dramatic rise in reports of limping elk in 2007-2008 prompted a scientific investigation into the underlying cause. Elk with the disease can have deformed, overgrown, broken or sloughed hooves. These lesions can be painful and cause limping or lameness when walking. Elk that show these signs do not necessarily have elk hoof disease, as there are many other potential diseases or injuries that could cause similar abnormalities to elk hooves. Some bull elk also have deformities of the opposite antler depending on the timing of the hoof infection with antler growth.

What causes the disease?

Scientists are still working to understand this disease better. The emergence of the disease is likely due to multiple factors related to the environment, overall health of the elk, and the presence of an infectious organism. Independent laboratories from the US and abroad that have detected bacteria in the genus *Treponema* causing damage in the affected hooves.

How does it spread?

This is still unknown but it is believed that this type of bacteria can be maintained and/ or transferred in moist soil via the hooves of elk and/ or other animals such as sheep and cows.

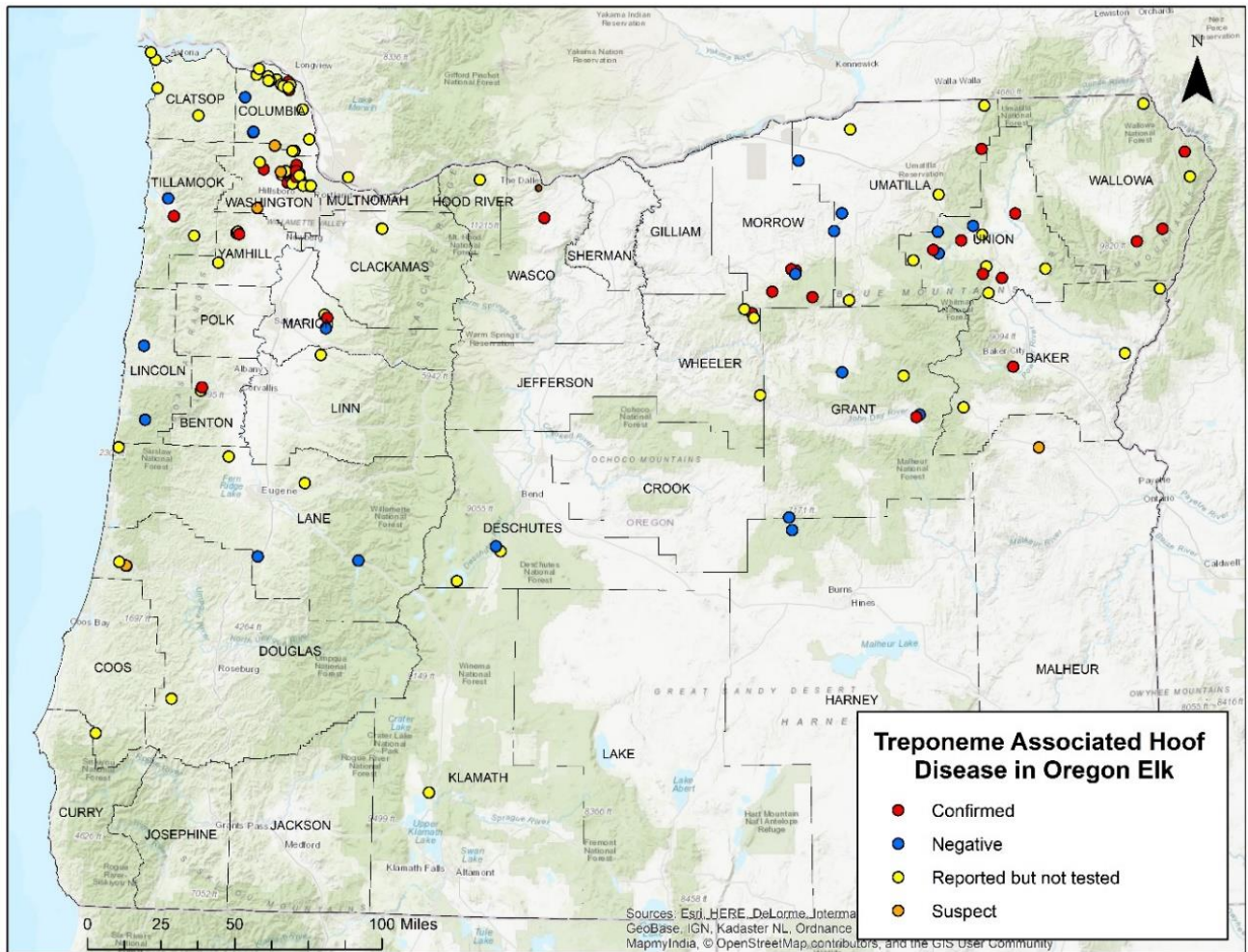
Is this disease affecting a specific age class or sex?

No. Elk hoof disease appears to be affecting all ages and both sexes of elk.

Where are we seeing hoof disease?

The disease is currently most predominant in southwest Washington, north of the Columbia River and has become more prevalent and widespread since the winter of 2007-2008. In Oregon, several hunter-harvested elk with suspicious hoof abnormalities and reports of limping elk have been reported from around the state. The first confirmed case came from Washington County in January of 2014 and initially clustered in northwest Oregon. Since then, confirmed cases of TAHD have been identified in Roosevelt elk in multiple counties as far south as Marion and Benton counties. Cases are scattered but occurring east of the Cascades in rocky mountain elk. ODFW is requesting the public to report observations of lame or hunter-harvested elk with hoof deformities on the ODFW elk

hoof disease reporting form, http://www.dfw.state.or.us/wildlife/health_program/elk_hoof_disease/, which can be found at www.odfw.com under Hunting.



Reports of limping elk using our on-line reporting tool between 2013 and October of 2017. The red dots represent elk that were confirmed to have TAHD, the blue dots represent elk that were negative for TAHD but had abnormal hooves, the yellow dots represent reports of limping elk, and the orange dots are cases where the animal had most of the characteristics of the disease but could not be confirmed.

How common is this disease?

In Washington, herds have been observed with 20-90% of the animals showing lameness. In Oregon, there has now been over thirty confirmed cases, and at least 70 separate reports of limping elk or elk with deformed hooves. A majority of the reports have been from the northwestern corner of the state an increasing number of cases are also showing up in northeast Oregon. Active surveillance is currently being conducted to determine the extent of infection in potentially affected herds.

Are other animals susceptible? Will my livestock be affected?

Cattle and sheep have been diagnosed with hoof diseases associated with Treponeme bacteria as well. These diseases are known as bovine digital dermatitis (DD) and contagious ovine digital dermatitis (CODD). However, it is unknown if cattle and sheep are susceptible to the same disease seen in elk. Other than elk, other ungulates do not appear to be developing similar hoof lesions in areas where TAHD is common. Transmission of the disease between

elk, sheep and cattle is not apparent and there have been no reports of an increase in hoof disease in domestic livestock.

Will hoof disease affect the meat of the elk I harvest?

No. There is also no evidence to suggest this disease poses a risk to human health. Examination of muscle tissue shows that the disease in the hooves does not extend to the meat or organs of the animal. However, chronically lame elk may be in poor body condition and appear thin due to reduced feeding or ability to access quality foraging areas from the painful condition.

Is the disease treatable?

Treatment of any disease in free-living wildlife is very difficult. In livestock, hoof diseases are often treated with repeated antibiotics and foot baths and managed by keeping their pens clean. Similar actions to treat wild elk are not practical.

How can I report an elk I've seen or harvested that looks like it has hoof disease?

Please visit our online site for reporting elk hoof disease:

http://www.dfw.state.or.us/wildlife/health_program/elk_hoof_disease/ (found at www.odfw.com under Hunting) or call our toll free number at 1-866-968-2600.

If you harvest an elk with diseased or overgrown hooves, please remove and remove the lower limbs for analysis. If possible, place each hoof in a separate plastic bag and label (i.e. front left). Place the hooves in a cool area, take digital photos of the affected hooves, and contact the Wildlife Health Lab by phone or email to arrange collection of the diseased hoof (or hooves).

What if I have additional questions?

You can contact our wildlife health team via e-mail at wildlife.health@state.or.us or you can call our wildlife health toll free number (1-866-968-2600).

